

3D X-RAY MICROSCOPIC ANALYSIS ON A PROSTHETICALLY LOADED IMPLANT WITH PLATFORM-SWITCHING AND CONICAL CONNECTION: A CASE REPORT

M. DI GIROLAMO¹, L. BAGGI², P. PIRELLI¹, L. PAPPALARDO², G. MASSEI³, F. IACULLI⁴, G. IEZZI⁴, A. PIATTELLI⁴, R. CALCATERRA²

¹ School of Dentistry, University of Rome "Tor Vergata", Rome, Italy

² Department of Social Dentistry, National Institute for Health, Migration and Poverty, Rome, Italy; School of Dentistry, University of Rome "Tor Vergata", Rome, Italy

³ National Institute of Geophysics and Volcanology (INGV) - The Vesuvius Observatory - Naples, Italy

⁴ Private Practice, Torino, Italy

⁵ Department of Medical, Oral and Biotechnological Sciences, University "G. d'Annunzio" Chieti-Pescara, Chieti, Italy

SUMMARY

The histological and histomorphometrical examination were the gold standard in the qualitative and quantitative analyses of the peri-implant tissue around the implant. In recent years, the field of microscopy has witnessed a considerable enhancement of the performance of microscopes that have very high resolution performance and allowing very sophisticated analysis even larger than traditional preparations. The possibility to have an affordable analyses of whole implant with the surrounding different tissues (soft and hard tissues) without the traditional pre-treatment necessary for the histological analysis may represent a goal to describe material properties and behaviors or simply to visualize structural details.

The aim of the present study were to evaluate a 3D X-ray microscopic analysis of peri-implant tissue compared to a traditional histological and histomorphometrical analysis of the peri-implant tissues around an implant with a conical connection associated with platform-switching in order to assess the validity of the new analysis technique.

Key words: marginal bone loss, morse taper connection, platform-switching, X-ray microscopes analysis.

Introduction

The use of dental implants in the rehabilitation of partial or total edentulism is proven to be a valid treatment with a high success rate (1).

To achieve the best treatment outcome in all implant systems, the implant has to be able to integrate with its surrounding tissue.

In particular, marginal bone loss (MBL) is considered as the key factor in the stability and longevity of dental implants, as well as the

maintenance of the peri-implant soft tissues (2). Marginal bone loss around dental implants is related to several factors: the establishment of a pathogenic microflora, promoting the occurrence of peri-implant diseases with a chronic mucosal inflammation, the increasing pocket depth and progressive bone resorption, as well as the role of biomechanical stress due to incorrect occlusal design (2-5).

Several studies focused the attention about the role of the implant-abutment connection design that may contribute to allow stability of the peri-

implant bone level. Specifically, implant-abutment geometry influences both bacterial and yeast colonization inside the implants (6, 7). The Morse taper conical internal connection had shown better results in terms of prevention of microbial penetration, sealing performance and implant stability (8-10). The lesser marginal gap between the implant and abutment in the conical connection induces a decrease of the bacterial penetration, thus preventing marginal bone loss (10). However, when a matching implant-abutment diameter is used, the inflammatory infiltrate is always located at the level of the implant-abutment interface and in tight contact with crestal bone, causing resorption of marginal bone.

One of the most important innovation was the introduction of the platform switching, that has determined important benefit in term of biomechanical behavior, influence upon bone crestal level, and soft tissue response (11, 12).

Currently, evaluation of those treatments in which abutments of lesser diameter were used revealed better preservation of the hard and soft tissues than treatment that use abutments with diameters matched to the implant (7, 13).

So far, the histological and histomorphometrical examination were the gold standard in the qualitative and quantitative analyses of the peri-implant tissue around the implant, even if the nature of specimens which consist of both, metal implant and soft/hard tissues poses difficulties in preparing the specimens for the analyses.

The main type of histological studies commonly used in dentistry are descriptive histology and histomorphometry. The descriptive is used to provide a general evaluation of the tissue of interest, including the morphology structure and arrangement of cells, matrix, implant and tissue implant interface.

Histomorphometry has been performed using histological slides and represent a methodology for quantitatively analyzing of parameters like bone apposition, bone ingrowth, etc. (14).

In recent years, the field of microscopy has witnessed a considerable enhancement of the performance of microscopes that have very high

resolution performance and allowing very sophisticated analysis even larger than traditional preparations.

In particular the method of X-ray microscopes (XRM) advanced imaging solutions that have removed major hurdles for three-dimensional imaging by achieving high contrast and submicron resolution imaging even for your relatively large samples. These groundbreaking advances in non-destructive, 3D imaging empower a broad range of technical disciplines including life science.

The possibility to revealing details of microstructure, ideally in three dimensions (3D), represent a critical part of understanding, especially in biological specimen constituted by different tissue and hard materials (i.e. titanium). The possibility to have an affordable analyses of whole implant with the surrounding different tissues (soft and hard tissues) without the traditional pre-treatment necessary for the histological analysis may represent a goal to describe material properties and behaviors or simply to visualize structural details.

The aim of the present study was to evaluate by the mean of a 3D X-ray microscopic the peri-implant tissues around an implant with a conical connection associated with platform-switching and to compare the results with the traditional histological and histomorphometrical analysis in order to assess the validity of the newly proposed technique.

Case report

A 61-year-old female patient was rehabilitated with a platform-switched conical connection implant [3,3 mm in diameter and 7,5 mm in length GTB- Plan1Health Amaro (UD) Italy] placed in the left posterior mandible (3.7 position). Briefly, the implant was inserted in crestal position and immediately received a healing abutment to allow an adequate remodelling of the gingival tissue. Two months after the surgery, a definitive abutment [Easy Abutment Slim GTB

Plan IHealth Amaro (UD) Italy] was placed, and the implant received a cemented temporary acrylic crown (Tempbond NE, Kerr, KaVo Kerr Group USA); 3 months later, a definitive gold alloy-resin crown was delivered. After 11 months from placement and 6 months of functional loading, the implant was removed for psychological distress reasons. Once retrieved, the whole implant with the surrounding hard and soft tissues were immediately stored in 10% buffered formalin and send to National Institute of Geophysics and Volcanology (INGV) - The Vesuvius Observatory – Naples for the X-ray analysis.

The whole implant was extracted from the formalin and placed in an appropriated stub without any intermediate passage, then analyzed with High resolution X-ray tomography tests under a 3D X-ray microscope (XRM, Xradia Versa XRM-410, Zeiss Corp., Oberkochen, Germany). A total of 1004 projections were acquired while the specimen was rotated about 360°. Then, the visualizations were fulfilled on CT vox (Bruker microCT, Kontich, Belgium) image analysis software.

Of the images obtained we analyzed only the part of implant system in contact with bone, removing the images related to coronal part of abutment and the prosthetic crown.

After the 3D microscopic analysis, the whole specimen was replaced in 10% buffered formalin and sent to the Implant Retrieval Center of the Department of Medical, Oral and Biotechnological Sciences of the University of Chieti-Pescara (Italy) for the histological evaluation. The specimen was processed as previously reported, according to Iezzi et al. and Bako et al. (15,16) and to the resin manufacturer instruction; briefly, the sample was dehydrated in an ascending series of alcohol rinses (70, 80, 90, and 100% ethanol) followed by an intermedium phase with xylene, and embedded in methylmethacrylate resin, Technovit 9100 New® (Heraeus Kulzer GmbH, Hanau, Germany). Technovit 9100 New® base solution was destabilized using a chromatography column filled with 50 g of Al₂O₃. Thus the sample was polymerized in a vacuum-sealed

condition and in the range of -2°C to -20°C; the polymerization solution was mixed immediately before using cooled stock solutions A and B (obtained according to manufacture instruction) in a ratio of 9:1.

After polymerization, the specimen was sectioned longitudinally along the major axis of the implants with a high-precision diamond disc at about 150 µm and ground down to about 30 µm with Precise 1 Automated System (Assing, Rome, Italy). The obtained slides were stained with basic fuchsin and toluidine blue. Histomorphometry of bone-implant contact percentage was carried out using a light microscope (Laborlux S, Leitz, Wetzlar, Germany) connected to a high resolution video camera (3CCD, JVC KY-F55B) interfaced to a monitor and PC (Intel Pentium III 1200 MMX). This optical system was associated with a digitizing pad (Matrix Vision GmbH) and a histometry software package with image capturing capabilities (Image-Pro Plus 4.5, Media Cybernetics Inc., Immagini & Computer Snc Milano, Italy).

Results

The 3D microscopic analysis reveals the presence of the bone around the whole implant surface (Figure 1 A), in particular the bone is detectable at platform level (Figure 1 B).

The traditional histological and histomorphometrical analysis showed, at lower magnification, bone tissue surrounding the whole implant, unless a limited area in the apical portion probably damaged during the harvesting procedure (Figure 2 A). At higher magnification, in the coronal portion of the implant, it was possible to observe bone directly in contact and even upon the platform level (Figure 2 B). A small amount of resorption (0.2 mm) could be detected at the vestibular aspect of the coronal bone; however, wide areas of bone remodeling with newly formed bone and numerous cement lines could be observed in the same region (Figure 2 B).

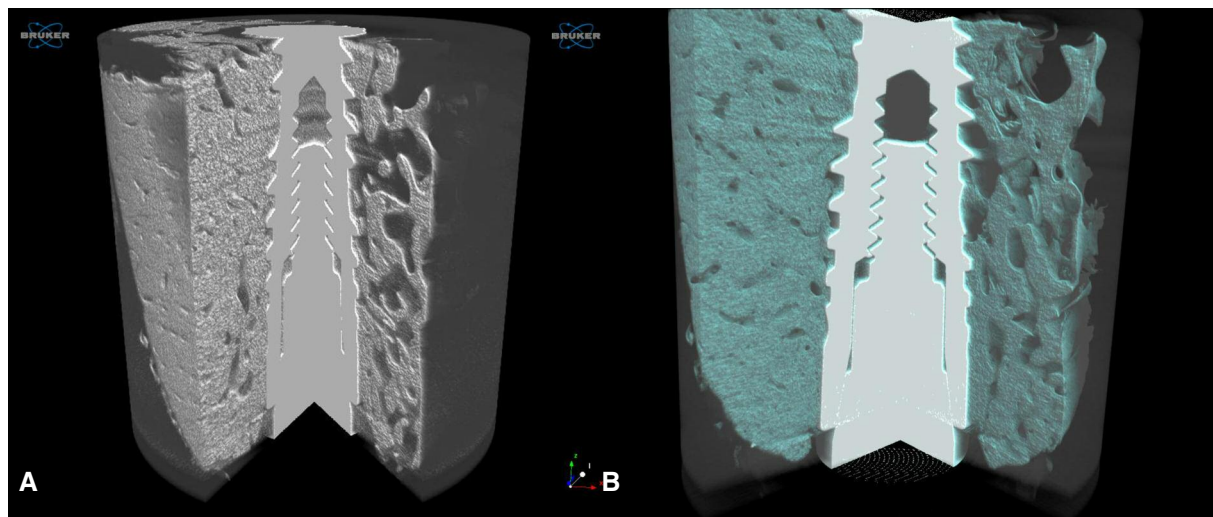


Figure 1
(A) XRM aspect of whole implant surrounded by bone and soft tissue in 3D. (B) the bone is detectable at platform level.

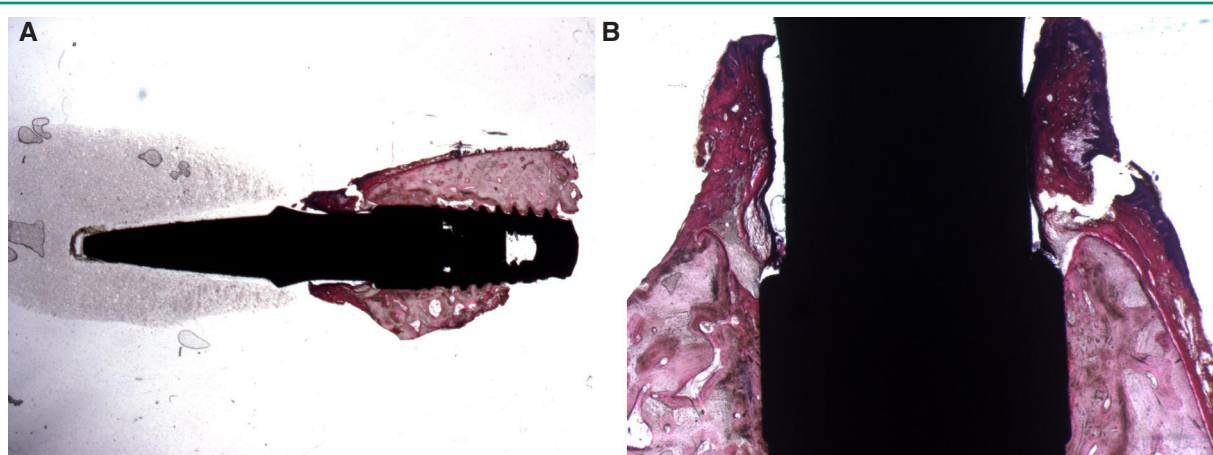


Figure 2
(A) Histological aspect of the whole implant surrounded by bone tissue after retrieval. Acid fuchsin-toluidine blue, original magnification 6X. (B) Bone in the coronal portion of the implant, in direct contact even upon the platform. Acid fuchsin-toluidine blue, original magnification 20X.

The 3D microscopic analysis reveals at the same time the behaviour of the soft tissues around the implant system (Figure 1).

Discussion

X-ray computed microtomography (microCT) which is conventionally used for determining the

structure of hard calcified tissues such as bone, can also be used to visualise the 3D morphology of intact non-calcified organs and organisms in the presence of X-ray contrast agents.

Instead, XRM provides a non destructive high resolution and high contrast tomography to reveal a wealth of complex microstructure in three dimension by avoiding mechanical sectioning (17-19).

So, XRM combines X-ray imaging with micro-

scope technology to enhance the spatial resolution to 0,7 μm .

The results of investigation confirmed that X-ray is useful for testing uniformity of tissue section and analysis of minor elements with reasonably good spatial.

The X-ray analyses of the specimen reveal a stackable images respect the traditional histological analyses, moreover offering a whole analyses of the specimen, permit a global vision of the different tissue around the implant (soft and hard tissue) and collect a more compressive information of the relationship of the tissue and the implant.

Another advantage of this technique is represented by the unnecessary pre-treatment of the specimen like in the traditional histological analyses.

Certainly, more studies are necessary to address the possibility to use this technique routinely, to date represent an important choose to better understand the relationship of the different tissue with the implant.

Conflict of interest

The Authors state they have no conflict of interest.

References

1. Misch CE, Degidi M. Five-year prospective study of immediate/early loading of fixed prostheses in completely edentulous jaws with a bone quality-based implant system. *Clin Implant Dent Relat Res*. 2003;5:17-28.
2. Berglundh T, Persson L, Klinge B. A systematic review of the incidence of biological and technical complications in implant dentistry reported in prospective longitudinal studies of at least 5 years. *J Clin Periodontol*. 2002;29 Suppl 3:197-212.
3. Di Girolamo M, Calcaterra R, Di Gianfilippo R, Arcuri C, Baggi L. Bone level changes around platform switching and platform matching implants: a systematic review with meta-analysis. *Oral Implantol (Rome)*. 2016 Nov 13;9(1):1-10.3.
4. Lindhe J, Meyle J. Peri-implant diseases: Consensus Report of the Sixth European Workshop on Periodontology. *J Clin Periodontol*. 2008;35(8 Suppl):282-5.
5. Rungsiyakull C, Rungsiyakull P, Li Q, Li W, Swain M. Effects of occlusal inclination and loading on mandibular bone remodeling: a finite element study. *Int J Oral Maxillofac Implants*. 2011;26(3):527-37.
6. Baggi L, Di Girolamo M, Mirisola C, Calcaterra R. Microbiological evaluation of bacterial and mycotic seal in implant systems with different implant-abutment interfaces and closing torque values. *Implant Dent*. 2013;22:344-350.
7. Calcaterra R, Di Girolamo M, Mirisola C, Baggi L. Effects of Repeated Screw Tightening on Implant Abutment Interfaces in Terms of Bacterial and Yeast Leakage in Vitro: One-Time Abutment Versus the Multi-screwing Technique. *Int J Periodontics Restorative Dent*. 2016 Mar-Apr;36(2):275-80.
8. Tripodi D, Vantaggiato G, Scarano A, Perrotti V, Piattelli A, Iezzi G, D'Ercole S. An in vitro investigation concerning the bacterial leakage at implants with internal hexagon and Morse taper implant-abutment connections. *Implant Dent*. 2012;21:335-339.
9. Assenza B, Tripodi D, Scarano A, Perrotti V, Piattelli A, Iezzi G, D'Ercole S. Bacterial leakage in implants with different implant-abutment connections: an in vitro study. *J Periodontol*. 2012;83:491-497.
10. Schmitt CM, Nogueira-Filho G, Tenenbaum HC, Lai JY, Brito C, Doring H, Nonhoff J. Performance of conical abutment (Morse Taper) connection implants: a systematic review. *J Biomed Mater Res Part A*. 2014;102A:552-574.
11. Annibali S, Bignozzi I, Cristalli MP, Graziani F, La Monaca G, Polimeni A. Peri-implant marginal bone level: a systematic review and meta-analysis of studies comparing platform switching versus conventionally restored implants. *J Clin Periodontol*. 2012;39:1097-1113.
12. Aslam A, Ahmed B. Platform-switching to preserve peri-implant bone: a meta-analysis. *J Coll Physicians Surg Pak*. 2016;26:315-319.
13. Farronato D, Santoro G, Canullo L, Botticelli D, Maiorana C, Lang NP. Establishment of the epithelial attachment and connective tissue adaptation to implants installed under the concept of "platform switching": a histologic study in minipigs. *Clin Oral Implants Res*. 2012;23(1):90-4.
14. YH An, KL Martin. *Handbook of histology methods for bone and cartilage*. Ed. Springer Science + Business Media LCC, New York 2013 pgg 19-31.
15. Iezzi G, Iaculli F, Calcaterra R, Piattelli A, Di Girolamo M, Baggi L. Histological and histomorphometrical analysis on a loaded implant with platform-switching and conical connection: a case report. *J Oral Implantol*. 2017 Mar 16.
16. Bako P, Bassiouni M, Eckhard A, Gerlinger I, Frick C, Löwenheim H, Müller M. Methyl methacrylate em-

- bedding to study the morphology and immunohistochemistry of adult guinea pig and mouse cochleae. *J Neurosci Methods*. 2015 Oct 30;254:86-93.
17. O'Connell MK, et al. The three-dimensional micro- and nanostructure of the aortic medial lamellar unit measured using 3D confocal and electron microscopy imaging. *Matrix Biol*. 2008;27:171-181.
 18. Schrauwen JTC, et al. A method for the quantification of the pressure dependent 3D collagen configuration in the arterial adventitia. *J Struct Biol*. 2012;180:335-342.
 19. Metscher BD. MicroCT for Developmental Biology: A Versatile Tool for High-Contrast 3D Imaging at Histo-

logical Resolutions. *Developmental Dynamics*. 2009; 238:632-640.

Correspondence to:

Dr.ssa Roberta Calcaterra
Department of Social Dentistry, National Institute for Health Migration and Poverty (INMP)
Via di San Gallicano 25/A
Rome, Italy
Phone: 0039 06 58558306
E-mail: r.calcaterra@yahoo.it